

Case Report

Plasmapheresis in the treatment of fatty liver of pregnancy: A case report

Tahereh Ashrafganjoei¹, Soha Mirreza^{1*}, Mitra Eftekhariyazdi², Forough Mortazavi³

¹ Department of Obstetrics and Gynecology, Preventative Gynecology Research Center, Imam Hossein Hospital, Shahid Beheshti University of Medical Sciences, Tehran, Iran

² Department of Obstetrics & Gynecology, School of Medicine, Sabzevar University of Medical Sciences, Sabzevar, Iran

³ Department of Midwifery, School of Medicine, Sabzevar University of Medical Sciences, Sabzevar, Iran

ARTICLE INFO

Received 05 September 2018
Accepted 12 December 2018
Published 06 April 2019

Available online at:
<http://npt.tums.ac.ir>

Key words:

pregnancy;
acute fatty liver;
plasma exchange;
plasmapheresis

ABSTRACT

Introduction: Acute fatty liver of pregnancy (AFLP) is a rare but lethal disease with liver involvement that appears in the third trimester of pregnancy. There is no specific treatment for AFLP. Because liver dysfunction is the most pathogenesis in AFLP the following hypothesis will be raised that plasma exchange can be useful.

Case Report: A 26-year-old mother was referred to our emergency ward with AFLP. The ultrasonography reported a single alive anhydramnios fetus at 34 weeks and fatty liver G1-2. Emergent cesarean was performed and the patient was then admitted to the intensive care unit. The day after surgery, our patient developed periumbilical tenderness and displayed abnormal coagulable factors. Ultrasonography reported 500cc liquid in the abdominal space. Relaparotomy was performed and during the next several days, her general condition worsened and supportive treatment was not effective and the patient experienced a seizure. We started plasmapheresis and after 10 days platelet levels started to rise, lactate dehydrogenase began to reduce, the edema reduced significantly, and her orientation became better. We continued plasmapheresis for about 20 sessions. After one month, the patient was discharged from the hospital in good general condition.

Conclusion: Plasmapheresis may be effective in the treatment of fatty liver of pregnancy.

Introduction

Acute fatty liver of pregnancy (AFLP) is a rare disease with liver involvement that appears in the third trimester of pregnancy and is characterized by microvascular fatty infiltration of hepatocytes leading to liver insufficiency, a disorder that is unique to human pregnancy. It is a lethal disease with 1/7000-1/15000 prevalence in pregnancy (1).

Its prevalent symptoms are jaundice, right upper quadrant, mid-epigastric pain, central nervous system involvement, disseminated intravascular coagulation (DIC), nausea,

vomiting, gastrointestinal bleeding, and acute renal failure (2).

The exact cause of AFLP and its pathogenesis is yet unknown but there is a well-established association between AFLP and inherited defects in beta-oxidation of fatty acids. The most-known cause is mitochondrial dysfunction in fatty acid oxidation that leads to fatty acid accumulation in hepatocytes and hepatic failure.

The pathophysiology is unknown. The woman who has heterozygous long-chain 3-hydroxyacyl-coenzyme A dehydrogenase (LCHAD) deficiency and her fetus is homozygous for this mutation. The mother cannot metabolize this additional fatty acid (3), so termination of pregnancy is a logical way to stop the accumulation.

* Corresponding Author: Soha Mirreza, Department of Obstetrics and Gynecology, Preventative Gynecology Research Center, Imam Hossein Hospital, Shahid Beheshti University of Medical Sciences, Tehran, Iran. Email: Sohamirreza@sbmu.ac.ir

Diagnosis is based on clinical and Para clinical findings like jaundice, elevated liver enzymes and fatty infiltration in the liver that may be seen with ultrasonography but its definite diagnosis is via liver biopsy (4). Because abnormal liver tests and coagulopathy usually start to become normal shortly after delivery, delivery is an important proceeding to reduce maternal and fetal mortality (5). In fact, termination of pregnancy is the first action to improve the prognosis. No specific treatment for AFLP has been proposed; however, hepatic failure compensation with a kind of filtration such as plasma exchange can be a treatment (3, 6) that increases the chance of recuperation with supportive treatment such as intravascular fluid and product [fresh frozen plasma (FFP), cryoprecipitate] infusion. We report a 26-year-old mother with AFLP who was cured with plasma exchange.

Case Report

A 26-year-old woman G2 P1 L1 at 34 weeks of pregnancy was referred to our emergency ward with jaundice, heartburn, abdominal pain, vaginal spotting without any sign of labor, and elevated liver enzymes. The ultrasonography reported a single alive anhydramnios IUGR male fetus at 34 weeks with 1370 grams weight and a liver of normal size with increased echo pattern and fatty liver G1-2. Based on these clinical and paraclinical findings and considering AFLP, emergent cesarean was performed; the patient was then admitted to the intensive care unit. The day after surgery, our patient developed periumbelical tenderness and displayed abnormal coagulative factors and a decrease in hemoglobin level. Therefore, another ultrasonography was performed and 500cc liquid in the abdominal space was reported. With suspicion of hemoperitoneum in base of coagulative disorder, relaparotomy

was performed. After the second surgery, the patient became agitated and gradually showed generalized edema. Combined with jaundice and deranged liver function tests, thrombotic thrombocytopenic purpura (TTP) was another potential diagnosis, so a peripheral blood smear and measurement of ADAMTS13 level were taken to rule out TTP. The results were normal, so we prescribed FFP and packed cells as a supportive treatment. Over the next several days, the agitation and generalized edema became severe. On the fifth day of admission the GCS dropped to 11-12, serum liver enzymes increased, partial thromoplastin time (PTT) prolonged, and platelet (PLT) levels decreased. Her general condition worsened and supportive treatment was not effective. The patient experienced a seizure on the same day and neurologist confirmed a mild left parietal lobe infarction in a brain CT (Fig-1).

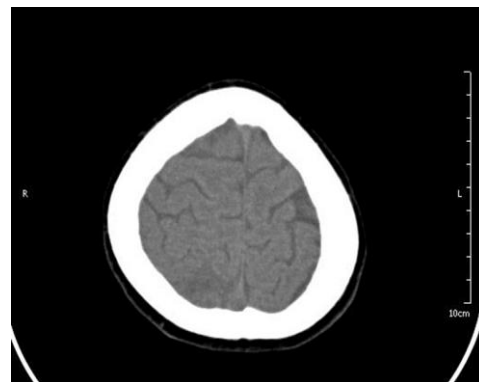


Figure1. Brain infarction in the left parietal lobe

An internist also confirmed the diagnosis of AFLP. Then, plasmapheresis began, and after 10 days PLT levels started to rise and lactate dehydrogenase began to reduce (Table1). We continued plasmapheresis for about 20 sessions. On the eleventh day, her orientation became better and the edema reduced significantly. After one month, the patient was discharged from the hospital in good general condition. We obtained an informed consent from the patient for publication of the present report.

Table1. Laboratory tests changes in admission period

	Normal Values* (20)	Swansea Criteria	1th Day	2th Day	10th Day	15th Day	20th Day	25th Day	Last Day
FBS¹ (mg/dL)	60-95	<72	100						86
Urea (mg/L)	3-11	9.5<	80						26
Creatinine (mg/dL)	0.4-0.8	1.7<	1						0.6
AST² (U/L)	4-32	42<	83		172		126	82	65
ALT³ (U/L)	2-25	42<	40		87		118	116	94
ALP⁴ (IU/L)	38-229	-	242		383		491	723	683
LDH⁵ (U/L)	82-524	-	1980		1045		872	632	438
Hb⁶ (mg/dL)	9.5-15	-	9.5	8	8.4	7.9	9.3	10.2	9.5
PLT⁷ (per micL)	146-429	-	41000	23000	74000	147000	186000	286000	295000
PTT⁸ (Second)	25-37	34<	31	43	37	38	37	42	36

* in the third trimester of pregnancy, ¹Fast Blood Sugar, ²Aspartate Aminotransferase, ³ Alanine Aminotransferase, ⁴Alkalan Phosphatase, ⁵Lactate Dehydrogenase, ⁶Hemoglobin, ⁷Patelete Count, ⁸Partial Thromboplastin Time

Discussion

The diagnosis of AFLP is challenging. Although the exact diagnosis of AFLP is made by liver biopsy, the diagnosis is usually based on clinical features, para clinical tests, and ruling out other diagnosis (7). We ruled out other diagnosis in this case. Finally, a consultation with an internist was performed and after ruling out other differential diagnosis and considering the patient's signs and symptoms, the diagnosis of AFLP was made. With the presence of Jaundice and significant elevated liver enzymes without proteinuria, hypertension, and pruritus, we rule out HELLP syndrome, preeclampsia, and cholestasis. Although a mild increase of liver enzymes usually exist in normal pregnancy, in AFLP and hepatitis they go up to 100-200 and 1000- 2000 respectively. In our patient, liver enzymes was higher than those in normal pregnancy and they was not as much as those in hepatitis; so, we ruled out hepatitis and normal changes in pregnancy. Sonography indicated a fatty liver G1-2 though ultrasound of liver has a low sensitivity and specificity and a high negative predictive value to detect AFLP (8). Our case presented jaundice. In preeclampsia, bilirubin is not so high to create jaundice. In preeclampsia, patient has

hypertension and proteinuria while our patient did not have hypertension and proteinuria. Hypoglycemia may be seen in AFLP and may not be seen. In this case, FBS was normal. ADAMS test was negative which rules out thrombotic thrombocytopenic purpura (TTP) in pregnancy.

A set of standard diagnostic criteria has been proposed referred to as the Swansea criteria. According to Swansea criteria, 6 or more of Swansea criteria in the absence of another explanation confirm diagnosis of AFLP (9); however, this criterion has not been widely accepted. This case fulfilled 6 of Swansea criteria for diagnosis of AFLP including jaundice, abdominal pain, increased prothrombin time, encephalopathy, elevated urea, and elevated transaminases.

Previous case reports showed that older women, primiparous, women with a male fetus, women with low BMI or twin pregnancy are at greatest risk of AFLP (7). However, our patient was young, multigravida2, with a single pregnancy. The chance is higher for those patients but AFLP does not limited to women with those characteristics. These can be the unique points of this case.

AFLP is a rare and lethal disease that occurs in late pregnancy with some

unspecific signs and symptoms such as nausea, vomiting, abdominal pain, coagulopathy, and CNS involvement. Bleeding, due to coagulopathy, and hepatorenal syndrome can cause renal dysfunction. Seizure and stroke (as was the case with our patient) can be CNS involvement symptoms. Hepatic dysfunction and renal involvement cause accumulation of toxic metabolites, so a kind of filtration can be useful in this condition. Plasmapheresis in theory can lead to the removal of ammonia endotoxins, bilirubin, and inflammatory cytokines from the circulation that must be performed by liver cells. In addition, injection of large volumes of FFP in this method can help to improve the DIC, and removing renin angiotensin and other vasoactive factors may improve renal function (10). We therefore tried to examine the effectiveness of plasmapheresis in our patient and after 20 sessions, she was cured although conservative treatment like fresh frozen plasma and IV fluid support was continued.

Nelson and colleagues reported 51 women with AFLP during 37 years in Parkland Hospital. In most patients with AFLP improvement within 24–48 hours of delivery occurred. However, in some cases, liver and renal function, mental status, and coagulopathy continued to worsen for up to a week postpartum (11). Women with AFLP usually receive supportive management in an intensive care unit (2, 12-15); however, in those complicated and severe cases, plasmapheresis has been recently used to improve maternal outcome. Martin's and his colleagues have utilized postpartum plasma exchange as supplemental therapy for six patients with severe AFLP. All patients responded with both clinical and laboratory improvement and no significant complications occurred (6).

Hartwell and Ma also treated a 19-year-old female with AFLP complicated by significant coagulopathy and encephalopathy who was treated with plasma exchange (16). Seyyed Majidi and Vafaeimanesh also reported three young women with AFLP who underwent plasmapheresis shortly after termination of pregnancy. Laboratory and clinical results showed improvement of the outcome. The duration of hospital stay and number of plasmapheresis sessions were reduced (17). Yu and his colleagues reported five AFLP patients with hepatic encephalopathy and renal failure who were subjected to plasma exchange and continuous renal replacement therapy. They declared that the treatment was effective and should be used immediately at the onset of hepatic encephalopathy and/or renal failure in patients with AFLP (18).

Ding's retrospective study on 22 cases (16 cases were treated with conventional treatment and 6 cases were treated with plasma exchange and plasma perfusion in addition to conventional therapy) revealed that five out of 6 patients who received plasma exchange and plasma perfusion improved, while 1 patient died. In the conventional therapy group, 3 patients improved, while 13 patients died of complications (19).

Conclusion

Plasma exchange may be a useful treatment method in patients who are severely ill at the time of admission or develop complications such as hepatic dysfunction despite emergency delivery.

Acknowledgement

Authors thank the patient for agreeing to publish this report.

Conflict of interest

The authors have no conflicts of interest.

References

1. Vigil-de Gracia P, Montufar-Rueda C. Acute fatty liver of pregnancy: diagnosis, treatment, and outcome based on 35 consecutive cases. *The Journal of Maternal-Fetal & Neonatal Medicine.* 2011 Sep 1;24(9):1143-6.
2. Nelson DB, Yost NP, Cunningham FG. Acute fatty liver of pregnancy: clinical outcomes and expected duration of recovery. *American journal of obstetrics and gynecology.* 2013 Nov 1;209(5):456-e1.
3. Barsoom MJ, Tierney BJ. Acute fatty liver of pregnancy (2011). *emedicine. medscape.com/article/1562425-overview.* Accessed January. 2013;21.
4. Wei Q, Zhang L, Liu X. Clinical diagnosis and treatment of acute fatty liver of pregnancy: a literature review and 11 new cases. *Journal of Obstetrics and Gynaecology Research.* 2010 Aug 1;36(4):751-6.
5. Reau, Nancy, Bacq Y. *The Liver in Pregnancy.* In: Schiff ER, Maddrey WC, Sorrell MF, editors. *Schiff's Diseases of the Liver.* 12 ed: Wiley-Blackwell; 2017. p. 1232
6. Martin Jr JN, Briery CM, Rose CH, Owens MT, Bofill JA, Files JC. Postpartum plasma exchange as adjunctive therapy for severe acute fatty liver of pregnancy. *Journal of Clinical Apheresis: The Official Journal of the American Society for Apheresis.* 2008;23(4):138-43.
7. Corton MM, Leveno K, Bloom S, Spong CY, Cunningham JD. *Williams obstetrics.* 24 ed. New York: McGraw Hill; 2010. 646-61 p.
8. Usta IM, Barton JR, Amon EA, Gonzalez A, Sibai BM. Acute fatty liver of pregnancy: an experience in the diagnosis and management of fourteen cases. *American journal of obstetrics and gynecology.* 1994 Nov;171(5):1342-7. PubMed PMID: 7977544. Epub 1994/11/01. eng.
9. Ch'ng CL, Morgan M, Hainsworth I, Kingham JG. Prospective study of liver dysfunction in pregnancy in Southwest Wales. *Gut.* 2002 Dec;51(6):876-80. PubMed PMID: 12427793. Pubmed Central PMCID: PMC1773454. Epub 2002/11/13. eng.
10. mBellig LL. Maternal acute fatty liver of pregnancy and the associated risk for long-chain 3-hydroxyacyl-coenzyme a dehydrogenase (LCHAD) deficiency in infants. *Advances in neonatal care: official journal of the National Association of Neonatal Nurses.* 2004 Feb;4(1):26-32. PubMed PMID: 14988877. Epub 2004/02/28. eng.
11. Nelson DB, Yost NP, Cunningham FG. Acute fatty liver of pregnancy: clinical outcomes and expected duration of recovery. *American journal of obstetrics and gynecology.* 2013 Nov 1;209(5):456-e1.
12. Liu G, Shang X, Yuan B, Han C, Wang Y. Acute Fatty Liver of Pregnancy: Analysis on the Diagnosis and Treatment of 15 Cases. *The Journal of reproductive medicine.* 2016;61(5-6):282-6.
13. Vigil-de Gracia P, Montufar-Rueda C. Acute fatty liver of pregnancy: diagnosis, treatment, and outcome based on 35 consecutive cases. *The Journal of Maternal-Fetal & Neonatal Medicine.* 2011 Sep 1;24(9):1143-6.
14. Yücesoy G, Özkan SÖ, Bodur H, Çakiroğlu Y, Çalışkan E, Özeren S. Acute fatty liver of pregnancy complicated with disseminated intravascular coagulation and haemorrhage: a case report. *International Journal of Clinical Practice.* 2005 Apr;59:82-4.
15. Liu G, Shang X, Yuan B, Han C, Wang Y. Acute Fatty Liver of Pregnancy: Analysis on the Diagnosis and Treatment of 15 Cases. *The Journal of reproductive medicine.* 2016;61(5-6):282-6.
16. Hartwell L, Ma T. Acute fatty liver of pregnancy treated with plasma exchange. *Digestive diseases and sciences.* 2014 Sep 1;59(9):2076-80.
17. Majidi S, Reza M, Vafaeimanesh J. Plasmapheresis in acute Fatty liver of pregnancy: an effective treatment. *Case reports in obstetrics and gynecology.* 2013;2013: 615975.
18. Yu CB, Chen JJ, Du WB, Chen P, Huang JR, Chen YM, Cao HC, Li LJ. Effects of plasma exchange combined with continuous renal replacement therapy on acute fatty liver of

pregnancy. *Hepatobiliary & Pancreatic Diseases International.* 2014 Apr 15;13(2):179-83.

19. Ding J, Han LP, Lou XP, Geng LN, Liu D, Yang Q, Gao S. Effectiveness of combining plasma exchange with plasma perfusion in acute fatty liver of pregnancy: a retrospective analysis.

Gynecologic and obstetric investigation. 2015;79(2):97-100.

20. Abbassi-Ghanavati M, Greer LG, Cunningham FG. Pregnancy and laboratory studies: a reference table for clinicians. *Obstetrics & Gynecology.* 2009 Dec 1;114(6):1326-31.